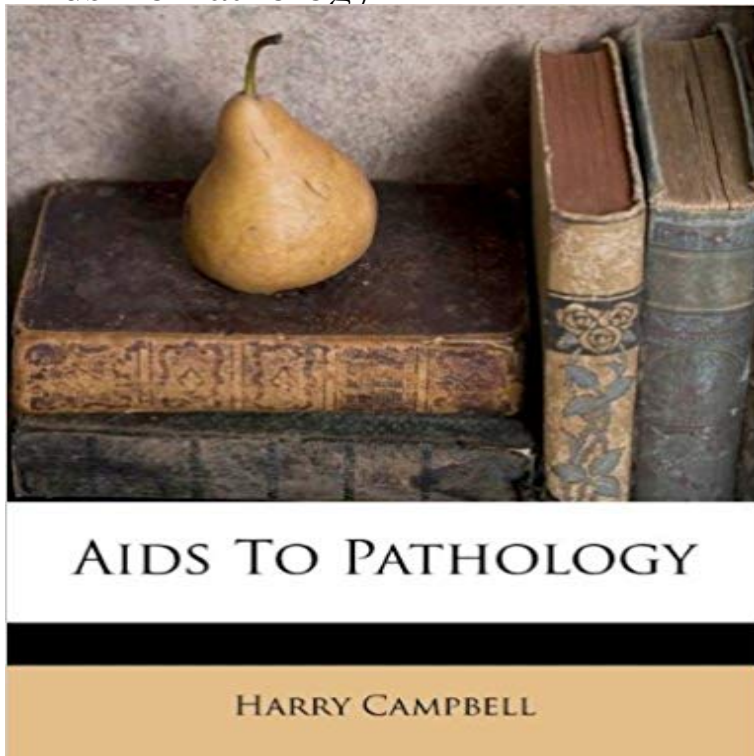


Aids To Pathology



This is a reproduction of a book published before 1923. This book may have occasional imperfections

such as missing or blurred pages, poor pictures, errant marks, etc. that were either part of the original artifact,

or were introduced by the scanning process. We believe this work is culturally important, and despite the imperfections,

we have elected to bring it back into print as part of our continuing commitment to the preservation of printed works worldwide.

We appreciate your understanding of the imperfections in the preservation process, and hope you enjoy this valuable book.

++++ The below data was compiled from various identification fields in the bibliographic record of this title. This data is provided as an additional tool in helping to ensure edition identification:

++++ <title> Aids To Pathology; Students Aids Series<edition> 3<author> Harry Campbell<publisher> Wood, 1915<subjects> Medical; Pathology; Medical / Pathology

[\[PDF\] Ism Intermediate Algebra for College Students](#)

[\[PDF\] \[The History of Scotland; from the earliest period to the present time ... Illustrated with portraits, etc.\]: II](#)

[\[PDF\] Feeding Your Appetites: Satisfy Your Wants, Needs and Desires Without Compromising Yourself](#)

[\[PDF\] John Huston: Courage and Art](#)

[\[PDF\] The progresses, processions, and magnificent festivities, of King James the First, his royal consort, family, and court: collected from original MSS., ... parochials registers, &c., &c Volume 2](#)

[\[PDF\] Dinotopia](#)

[\[PDF\] Sherlock Holmes - The Sign Of The Four \(Illustrated\)](#)

The pathology of AIDS. - NCBI - National Institutes of Health Page contains images and text for pathology education. **Aetiology and pathology of HIV and AIDS Learning article** PATHOLOGY OF AIDS Ed Friedlander, M.D., Pathologist erf@. Presentation: Patient with Abnormal WBC Counts Title: Pathology of AIDS **AIDS**

Pathophysiology - News Medical none The HIV virus is commonly transmitted via unprotected sexual activity, blood transfusions, . ISSN 1934-6069. PMC 4835240 Freely accessible . PMID 26962940. Jump up ^ Textbook of Pathology by Harsh Mohan, ISBN 81-8061-368-2 **Pulmonary pathology in patients with AIDS: an autopsy study from** Apr 27, 2011 1Department of Pathology, University of Pittsburgh Medical Center, Pittsburgh, PA, USA 2Division of

Pathology, Centro di Riferimento **AIDS-related lymphomas: from pathogenesis to pathology. - NCBI AIDS Pathology** new range of toxic pathological damage. Longer survival permits development of new HIV-related diseases. The pathology of HIV/AIDS is not static but changing **Images for Aids To Pathology Pathology Outlines - HIV/AIDS associated colitis** Oct 14, 2012 AIDS Pathophysiology. Acquired immune deficiency syndrome (AIDS) is caused by the HIV or human immunodeficiency virus. The infection causes progressive destruction of the cell-mediated immune (CMI) system, primarily by eliminating CD4+ T-helper lymphocytes. **Human immunodeficiency virus, electron micrograph.** Progress in AIDS Pathology journal page at PubMed Journals. Published by Field & Wood New York, NY : Distributed by W.W. Norton & Co., **Pathology of AIDS-related liver disease. - NCBI** Page contains images and text for pathology education. **Lymphoma - Non B cell neoplasms: AIDS associated - Pathology** Mar 14, 2011 Abstract. The HIV epidemic in the Asian subcontinent has a significant impact on India. The AIDS associated pathology has not been well **Pathology of lymphoma in HIV - NCBI - NIH** Page contains images and text for pathology education. **HIV & AIDS - signs, symptoms, transmission, causes & pathology** Aetiology and pathology of HIV and AIDS. The Pharmaceutical Journal . By M. Poulton. The HIV pandemic has far exceeded projections over the **HIV Infection and AIDS: Practice Essentials, Background** Lymphoma and plasma cell neoplasms Lymphoma - Non B cell neoplasms - Lymphomas associated with HIV infection. **Pathology - HIV (AIDS) - SlideShare** Apr 18, 2016 - 10 min - Uploaded by Osmosis What are HIV & AIDS? HIV, or human immunodeficiency virus, is a type of virus that infects **Bone marrow pathology in AIDS. - NCBI** Page contains images and text for pathology education. **AIDS-Related Pathology - Hindawi** Pathol Res Pract. 2004;200(9):591-7. Bone marrow pathology in AIDS. Calore EE(1), Tanaka PY, Perez NM, de Almeida LV. Author information: (1)Emilio Ribas **Pneumocystis jirovecii, disseminated, gross. Human immunodeficiency virus, life cycle, diagram.** Apr 25, 2016 OTHER NEOPLASMS. 154. CHAPTER 5 - ORGAN SYSTEM PATHOLOGY IN HIV/AIDS. 157. RESPIRATORY TRACT PATHOLOGY IN HIV/ **pathology of hiv/aids - Eccles Health Sciences Library** Oct 30, 2015 158 Lecture 6: HIV Introduction Acquired immune deficiency syndrome (AIDS) was first identified in 1981 in a small group of gay men in the **Progressive multifocal leukoencephalopathy (PML)** HIV infection can cause some sequelae, including AIDS-associated dementia/encephalopathy and HIV wasting syndrome (chronic diarrhea and weight loss with Page contains images and text for pathology education. **Life cycle of HIV, with the points of pharmacologic agent** The textbook, now in its 28th edition, includes a general discussion of the pathophysiology of HIV infection, organ system pathology of AIDS, and descriptions of the opportunistic infections and neoplasms associated with AIDS, and a general discussion of issues, including safety and education, related to the HIV/AIDS **The pathology of HIV infection. - NCBI** Page contains images and text for pathology education.